

Nouveautés en médecine interne

Dr Marc-Antoine DELBARRE

CHU Lille

Médecine Interne & Immunologie Clinique

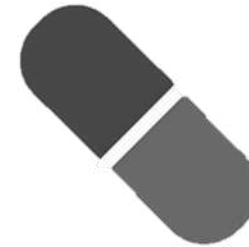

L'amylose en médecine interne ?



Diagnostic

- ✓ TTR
- ✓ AL
- ✓ AA

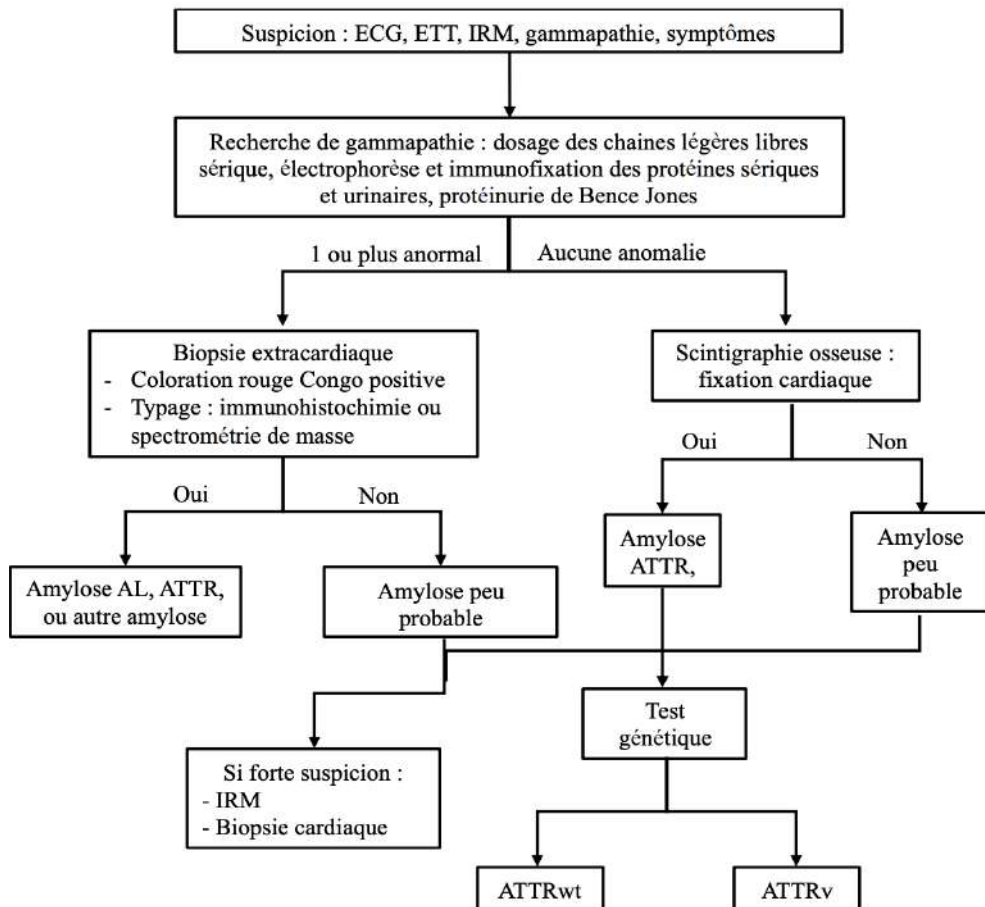


Traitement

- ✗ TTR
- ✗ AL
- ✓ AA



Distinguer les AL et les TTR cardiaques



Panoplie d'examens pour diagnostiquer et typer :

- Biomarqueurs : EPPS, IF, CLL, BJ...
- Imageries : ETT, scintigraphie ⁹⁹Tc, IRM...

Limites bien connues

- Forte prévalence de gammopathies chez patients âgés
- Aucun examen non invasif pour différencier AL et ATTR

Recours aux biopsies souvent nécessaire... Alors que leur rentabilité est faible dans la TTR

Est-il possible de typer sans biopsier ?



*Nouveaux **radiotraceurs**
spécifiques AL / ATTR*



*Nouveaux **biomarqueurs**
spécifiques AL / ATTR*



Nouveaux radiotraceurs ?

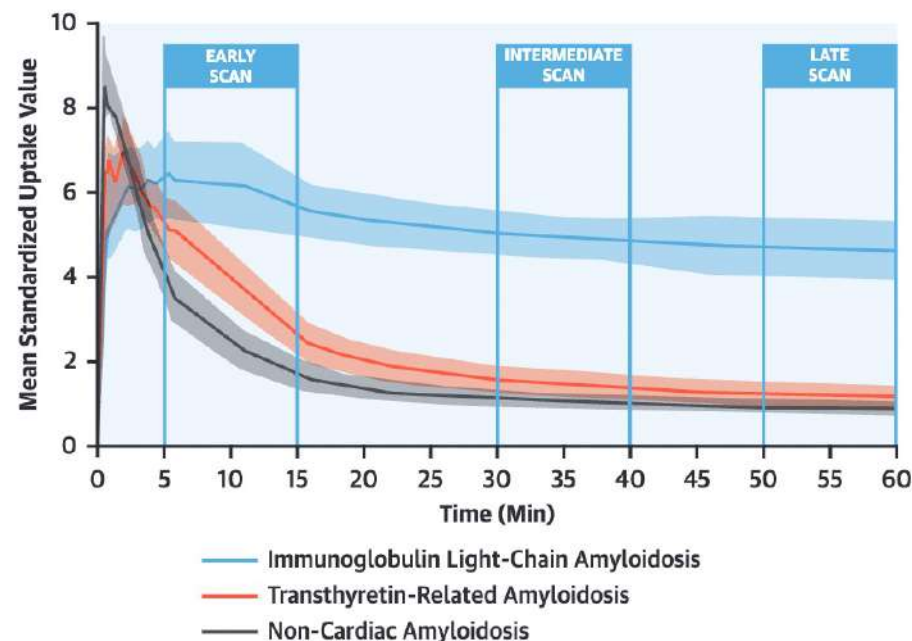
ORIGINAL RESEARCH

[18F]-Florbetaben PET/CT for Differential Diagnosis Among Cardiac Immunoglobulin Light Chain, Transthyretin Amyloidosis, and Mimicking Conditions

2021

Dario Genovesi, MD,^{a,*} Giuseppe Vergaro, MD, PhD,^{b,c,*} Assuero Giorgetti, MD,^{a,*} Paolo Marzullo, MD,^a Michele Scipioni, ENGd,^d Maria Filomena Santarelli, ENGd,^e Angela Pucci, MD,^f Gabriele Buda, MD,^g Elisabetta Volpi, BSc, PhD,^h Michele Emdin, MD, PhD^{b,c}

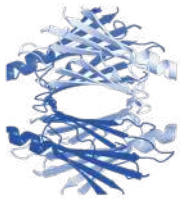
- **Cinétique d'élimination** du radiotraceur dans le myocarde pour distinguer l'AL de la TTR...



Prometteur, mais une étude de l'ISA montre 4/17 (24%) AL MAYO 2 : pas de rétention tardive



Nouveaux biomarqueurs



Structure-specific peptide probes reveal aggregated transthyretin in plasma of transthyretin amyloidosis patients

Pedretti R¹, Wang L¹, Nguyen AB¹, Hanna M², Benson M³, Grodin JL⁴, Tang WWH², Masri A⁵, Saelices L¹

UT Southwestern
Medical Center

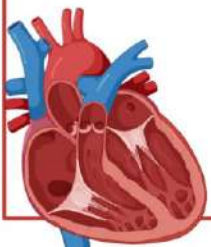


Exposed
ATTR-I84S

Open
ATTR-I84S

Closed
ATTRwt (5x)
ATTR-P24S
ATTR-V30M
ATTR-T60A
ATTR-I84S
ATTR-V122I
(type a)

Locked
ATTR-V122I
(type b)



Structure commune à tous les génotypes d'ATTR (en noir)

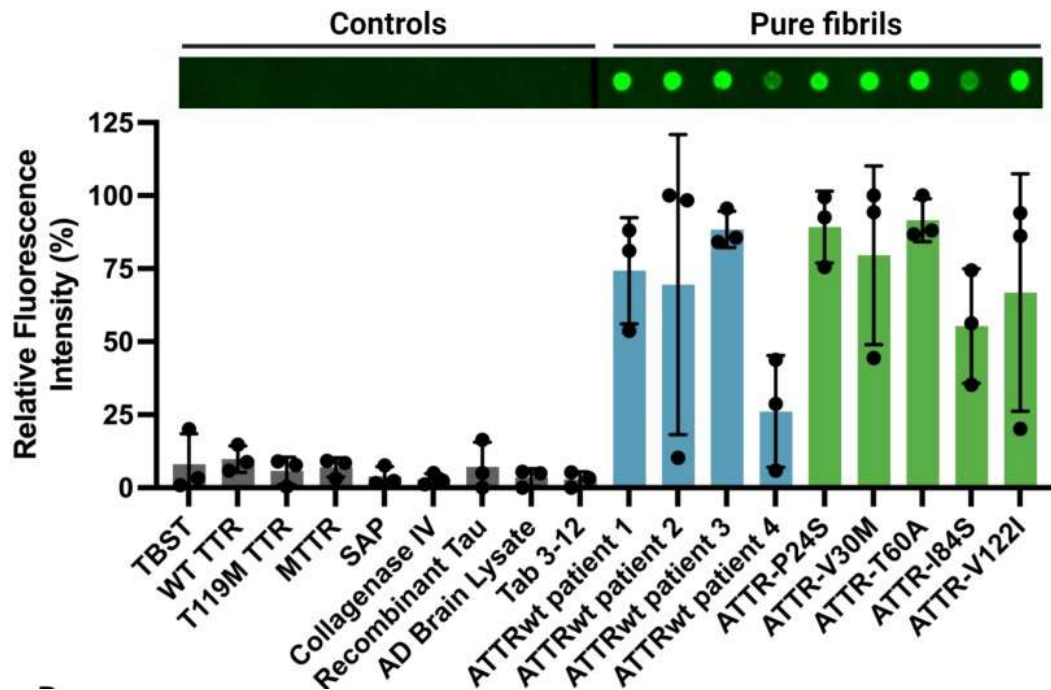


Développement d'une sonde ciblant la structure commune aux fibrilles ATTR

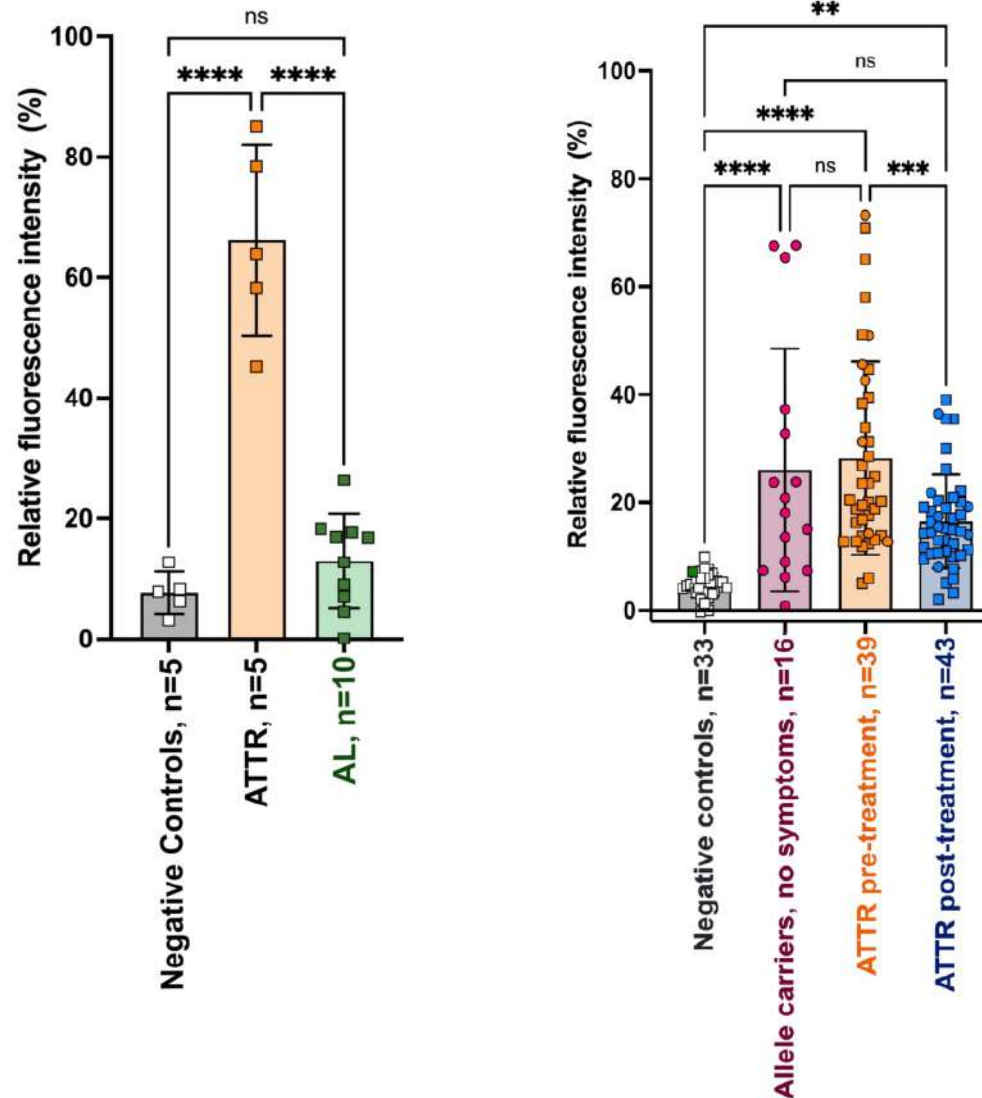


Nouveaux biomarqueurs

Détection tissulaire d'ATTR



Détection plasmatique d'ATTR



Permettrait :

- ✓ De typer sur tissu
- ✓ De différencier AL et ATTR sur prise de sang
- ✓ De suivre la réponse au traitement
- ✓ De détecter les porteurs asymptomatiques



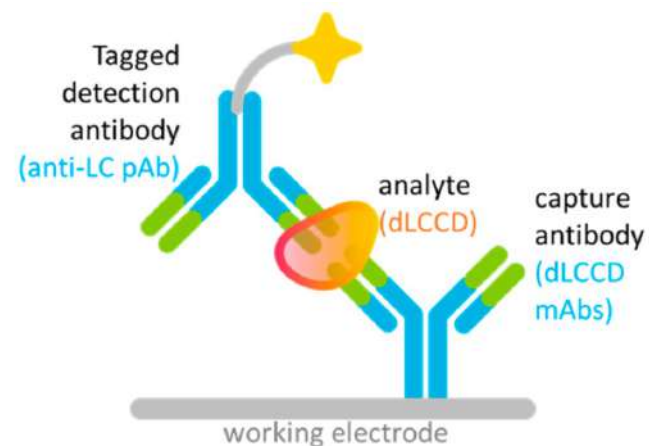
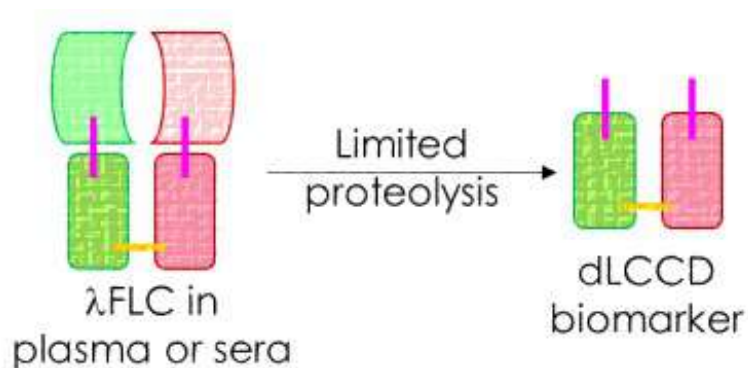
Nouveaux biomarqueurs



AmyLite™ Assay Quantifies Kinetically Unstable Circulating Amyloidogenic λ FLC Diagnostic and Prognostic Implications for λ AL Amyloidosis

Jianying Wang¹, Yao-Cheng Leo Li¹, Alex Jackman¹, Nathan Onpaeng¹, Eli Muchtar², Angela Dispenzieri², Vaishali Santhorawala³, Tatiana Prokhaeva³, Brian Spencer³, Jeffery W. Kelly⁴, Richard Labaudiniere

¹ Protego Biopharma, Inc., San Diego, California, USA; ² Mayo Clinic, Rochester, Minnesota, USA; ³ Boston University Amyloidosis Centre, Boston, Massachusetts, USA; ⁴ Scripps Research Institute, La Jolla, California, USA



Application d'une protéolyse limitée à la CL Lambda

- ✓ Seules CL Lambda amyloïdogènes génèrent les dLCCD (dimeric LC constant domain)
- ✓ Le néo-épitope des dLCCD est hautement conservé (99% des LLC)

Détection dLCCD grâce à Acps spécifique



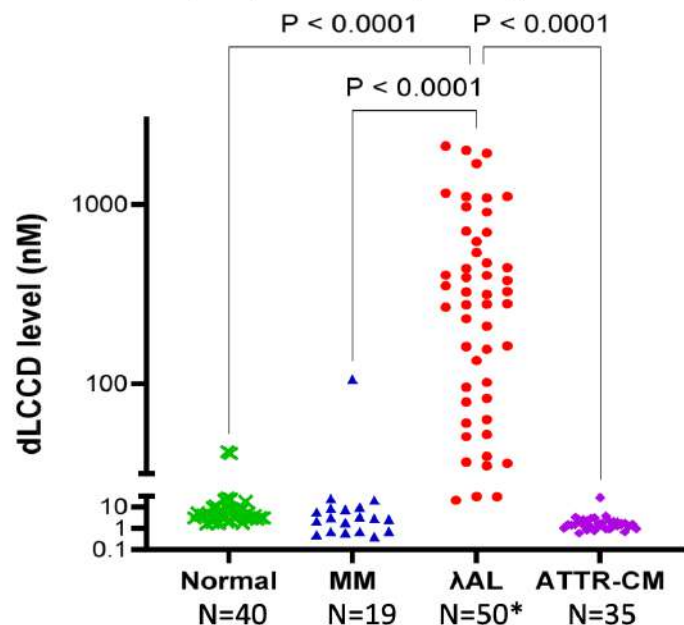
Nouveaux biomarqueurs



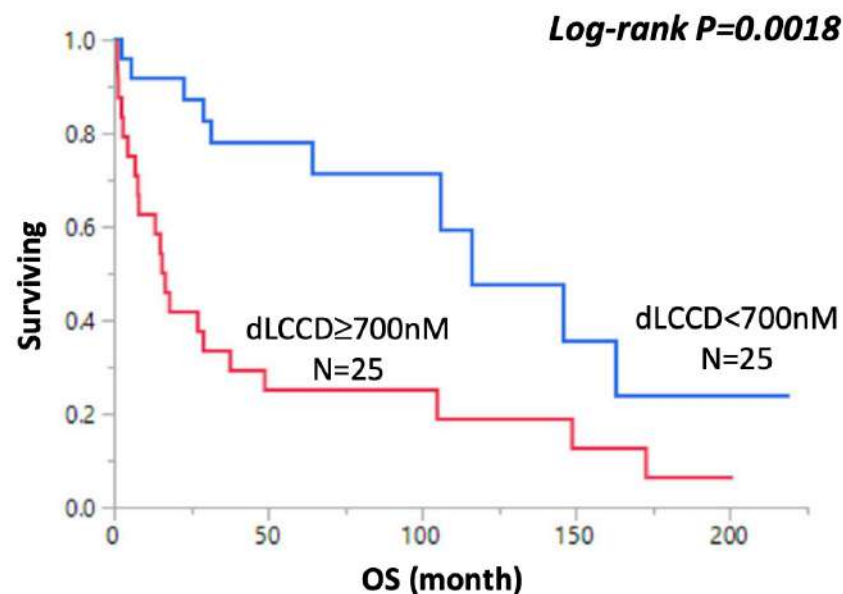
AmyLite™ Assay Quantifies Kinetically Unstable Circulating Amyloidogenic λFLC Diagnostic and Prognostic Implications for λAL Amyloidosis

Jianying Wang¹, Yao-Cheng Leo Li¹, Alex Jackman¹, Nathan Onpaeng¹, Eli Muchtar², Angela Dispenzieri², Vaishali Sancharawala³, Tatiana Prokaeva³, Brian Spencer³, Jeffery W. Kelly⁴, Richard Labaudiniere
¹ Protego Biopharma, Inc., San Diego, California, USA; ² Mayo Clinic, Rochester, Minnesota, USA; ³ Boston University Amyloidosis Centre, Boston, Massachusetts, USA; ⁴ Scripps Research Institute, La Jolla, California, USA

Plasma samples post limited proteolysis



Intérêt diagnostic...



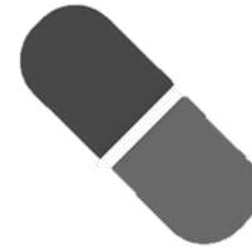Mais également pronostic !

L'amylose en médecine interne ?



Diagnostic

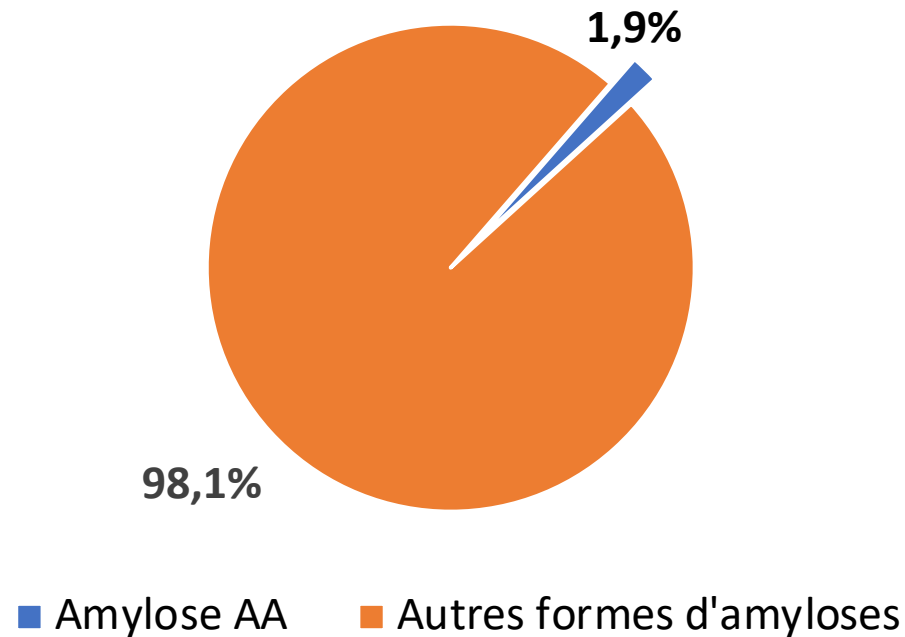
- ✓ TTR
- ✓ AL
- ✓ AA



Traitement

- ✗ TTR
- ✗ AL
- ✓ AA

L'amylose AA à l'ISA ?



Communications dédiées à l'AA = 10 / 533

Stratification de l'amylose AA ?

BIOMARKER-BASED RENAL RESPONSE AND PROGRESSION CRITERIA IN AA AMYLOIDOSIS: RESULTS FROM THE PAVIA-HEIDELBERG STUDY



UNIVERSITÄT
KLINIKUM
HEIDELBERG

AMYLOIDOSEZENTRUM



UNIVERSITÀ
DI PAVIA

Marco Basset¹, Ute Hegenbart², Laura Obici¹, Eloisa Riva³, Paolo Milani¹, Ettore Pasquinucci⁴, Andrea Foli¹, Martina Nanci¹, Martina Ciardo¹, Chiara Corpina¹, Claudia Bellofiore¹, Francesca Benigna¹, Pietro Benvenuti¹, Giuseppe Sanna¹, Roberta Mussinelli¹, Mario Nuvolone¹, Riccardo Albertini⁵, Giampaolo Merlini¹, Stefan Schönland², Norbert Blank², Giovanni Palladini¹

¹Amyloidosis Research and Treatment Center, IRCCS Policlinico San Matteo and Department of Molecular Medicine, University of Pavia; ²Division of Hematology, Oncology and Rheumatology, Department of Internal Medicine V, Amyloidosis Center, Heidelberg University Hospital; ³Hematology Department, Hospital de Clinicas, Facultad de Medicina, Montevideo; ⁴Nephrology and Dialysis Unit, A. Manzoni Hospital,

Objectif : développer et valider un score pronostique (rénal) dans l'AA

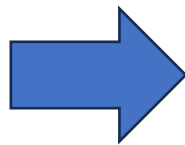
ROC pour cut-offs de protU et DFG associés à **dialyse à m24**

Cohorte **TEST**



UNIVERSITÀ
DI PAVIA

n = 147



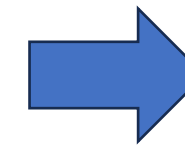
Réponse rénale	↓ protU > 40% sans ↑ DFG > 20%
Progression rénale	↑ DFG > 20%
Normalisation SAA	SAA < 6.4 mg/L

Cohorte **VALIDATION**

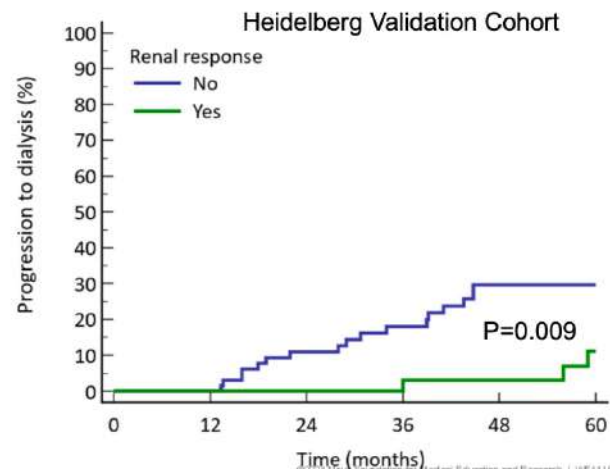
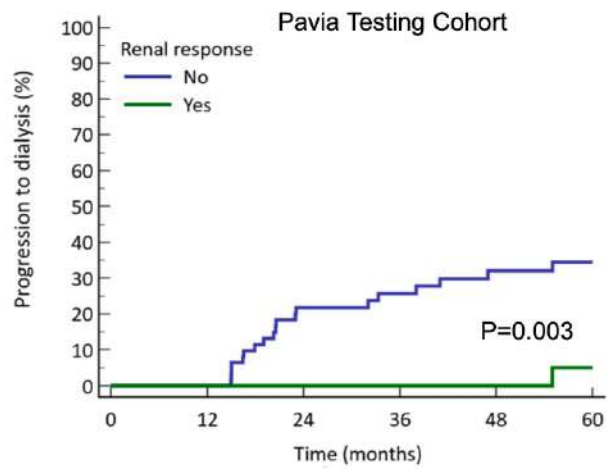


UNIVERSITÄT
KLINIKUM
HEIDELBERG

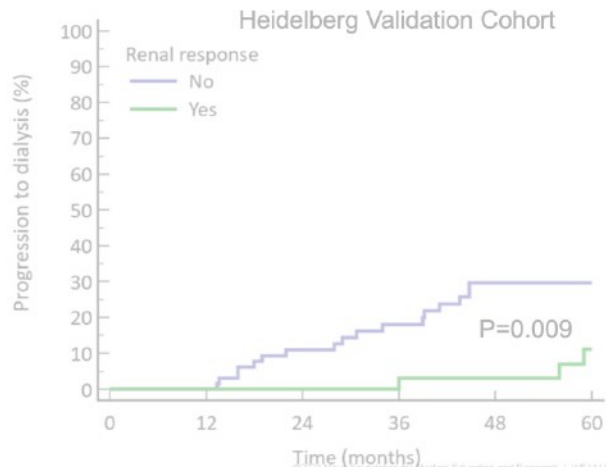
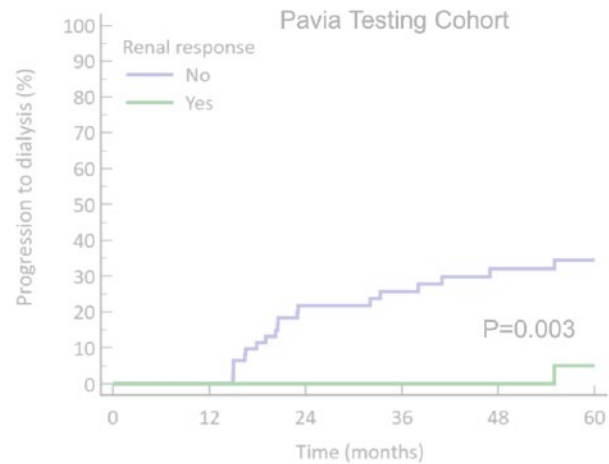
n = 156



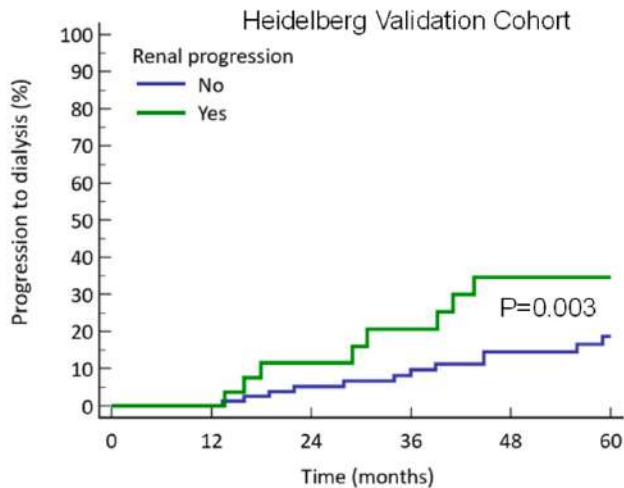
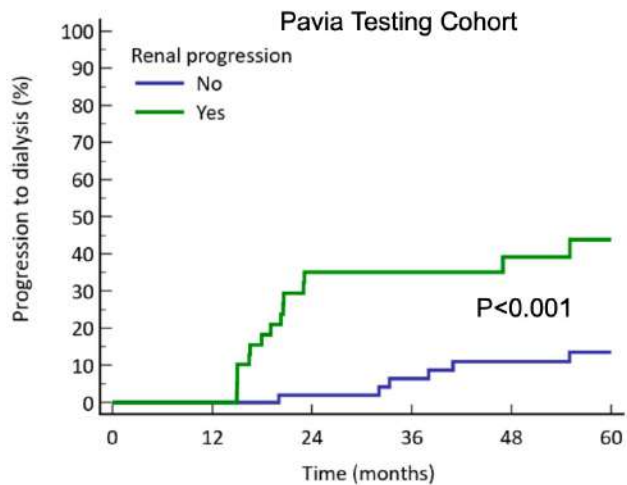
Réponse rénale ↓ protU > 40% sans ↑ DFG > 20%



Réponse rénale ↓ protU > 40% sans ↑ DFG > 20%

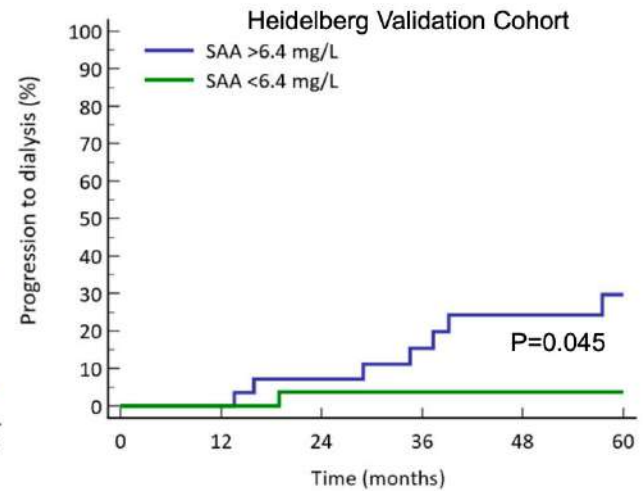
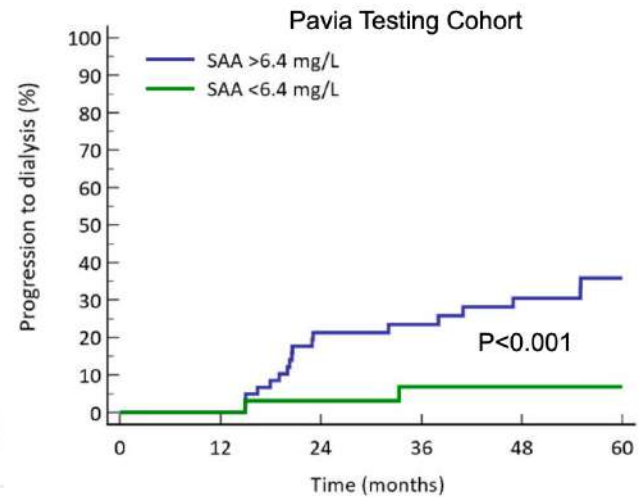
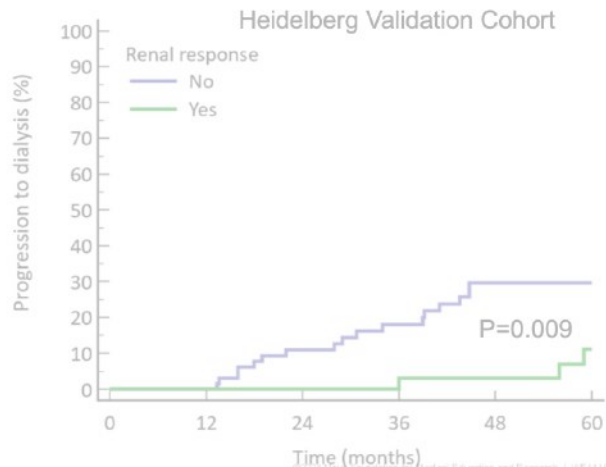
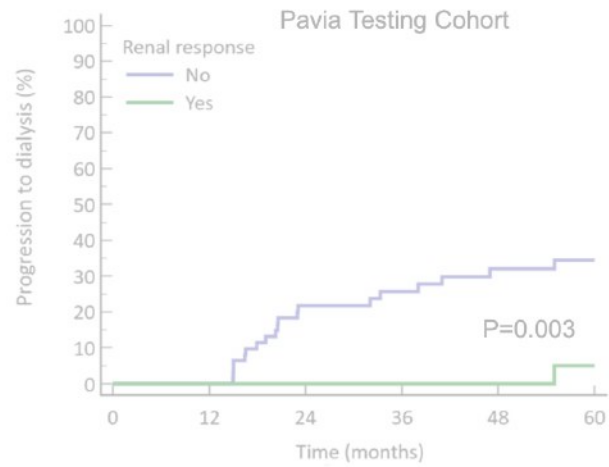


Progression rénale ↑ DFG > 20%

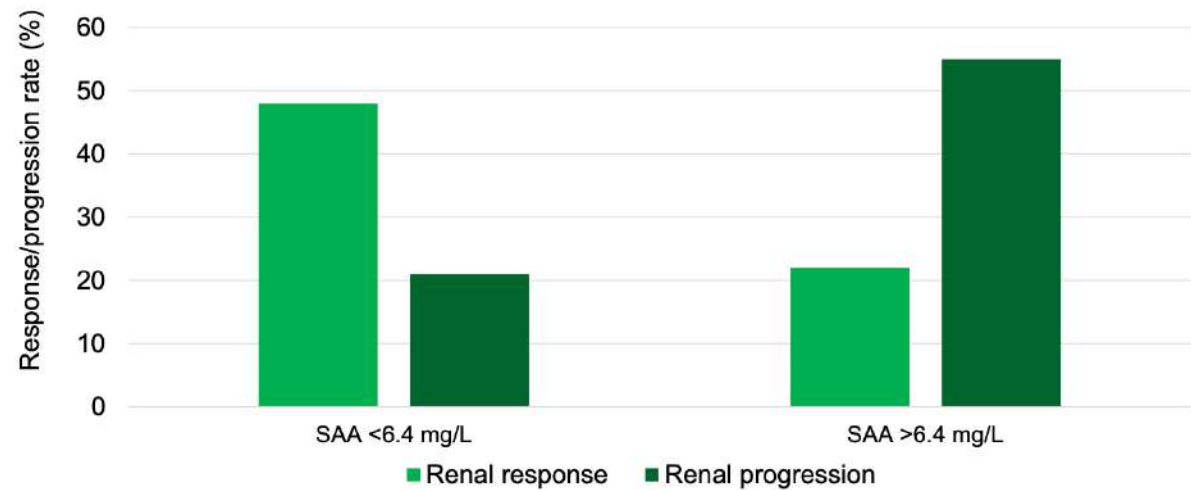
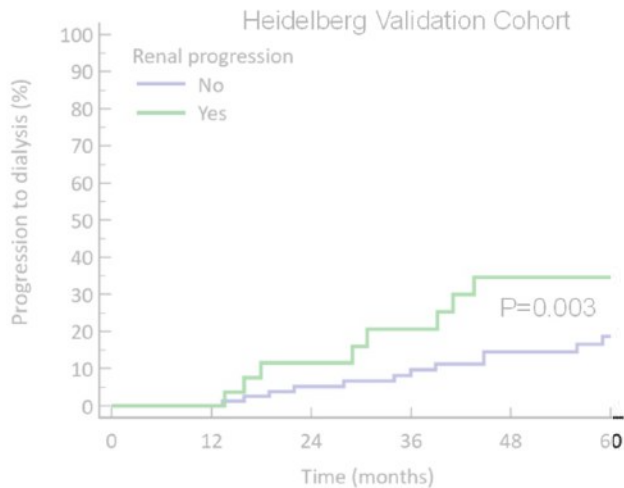
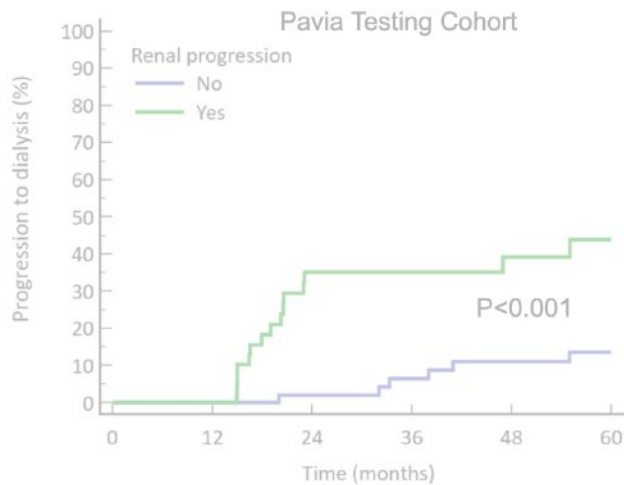


Réponse rénale ↓ protU > 40% sans ↑ DFG > 20%

Normalisation SAA < 6.4 mg/L

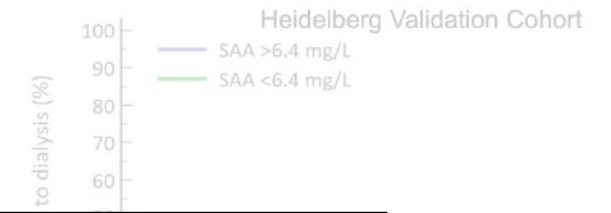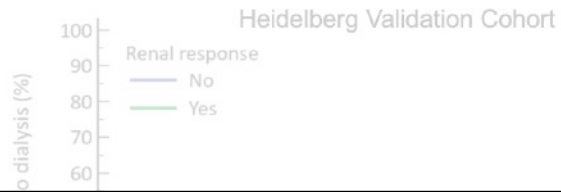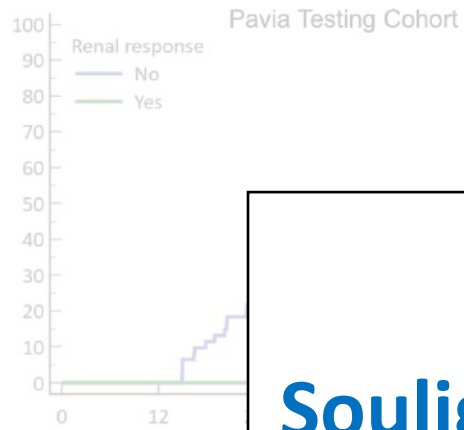


Progression rénale ↑ DFG > 20%



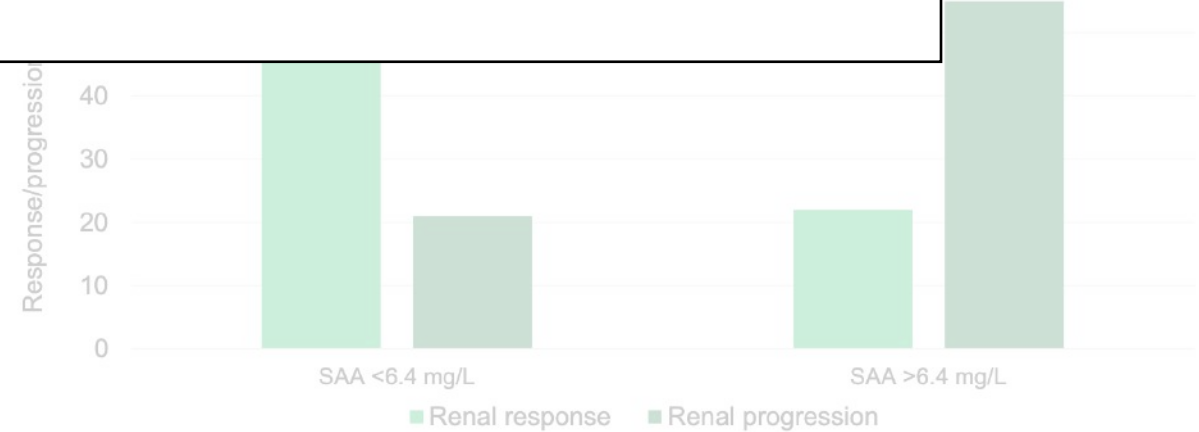
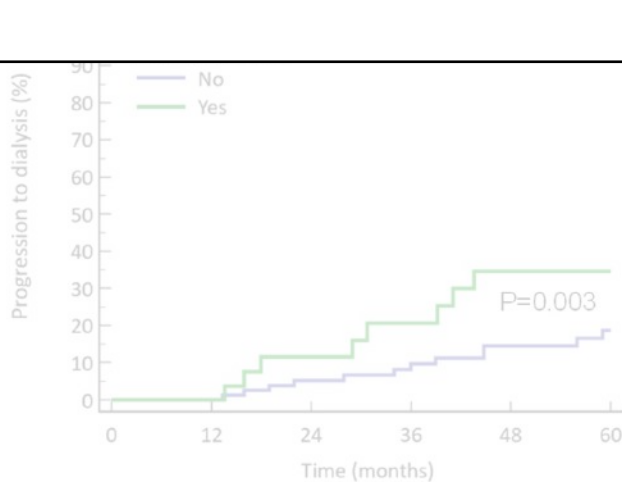
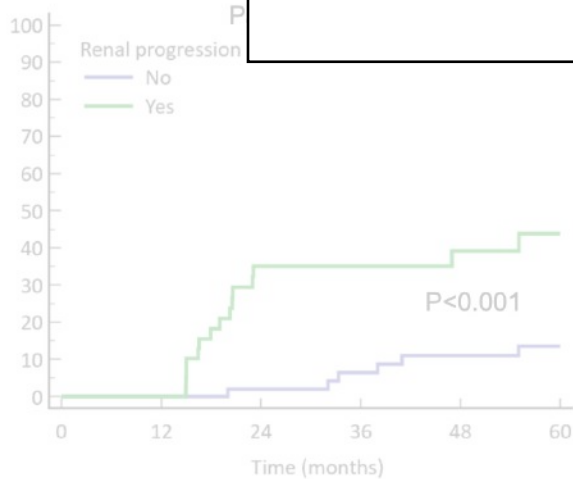
Réponse rénale ↓ protU > 40% sans ↑ DFG > 20%

Normalisation SAA < 6.4 mg/L



Souligne l'importance de la normalisation de la SAA...

Que faire si difficultés à normaliser la SAA ?



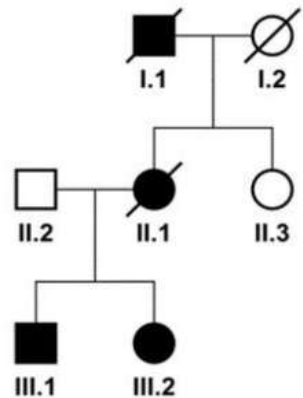
Antisense oligonucleotide therapy for familial AA amyloidosis, A N of 1 trial

Nelson Leung^{1,2}, Tereza Kmočová^{3,*}, Ellen D McPhail⁴, Surendra Dasari⁵, Lenka Nosková³, Aleš Hnízda³, Kateřina Hodaňová³, Martina Živná^{3,6}, Samih H Nasr⁴, Jakub Sikora^{3,6}, Jason D. Theis⁴, Julie A. Vrana⁴, Stanley T Crooke⁷, Anthony Bleyer^{3,8}, Stanislav Kmoč^{3,8}

¹Division of Nephrology and Hypertension, Mayo Clinic, Rochester, Minnesota, USA, ²Division of Hematology, Mayo Clinic, Rochester, Minnesota, USA, ³Research Unit for Rare Diseases, Department of Pediatrics and Inherited Metabolic Disorders, First Faculty of Medicine, Charles University in Prague, Czech Republic, ⁴Department of Laboratory Medicine and Pathology, Mayo Clinic, Rochester, Minnesota, USA, ⁵Department of Quantitative Health Sciences, Mayo Clinic, Rochester, Minnesota, USA, ⁶Institute of Pathology, First Faculty of Medicine, Charles University in Prague and General Teaching Hospital in Prague, Prague, Czech Republic, ⁷Novartis, Emeryville, California, USA, ⁸Section on Nephrology, Wake Forest University School of Medicine, Winston-Salem, NC, USA

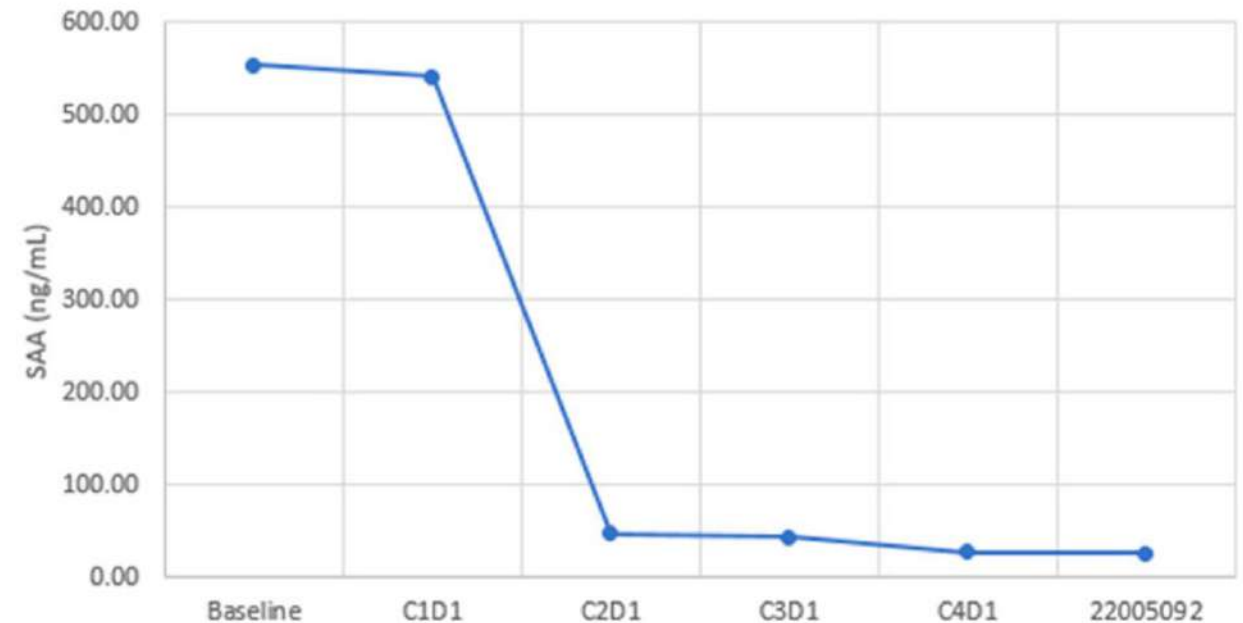
Institute of Pathology, First Faculty of Medicine, Charles University, Prague, Czech Republic

Description d'un cas familial d'amylose AA



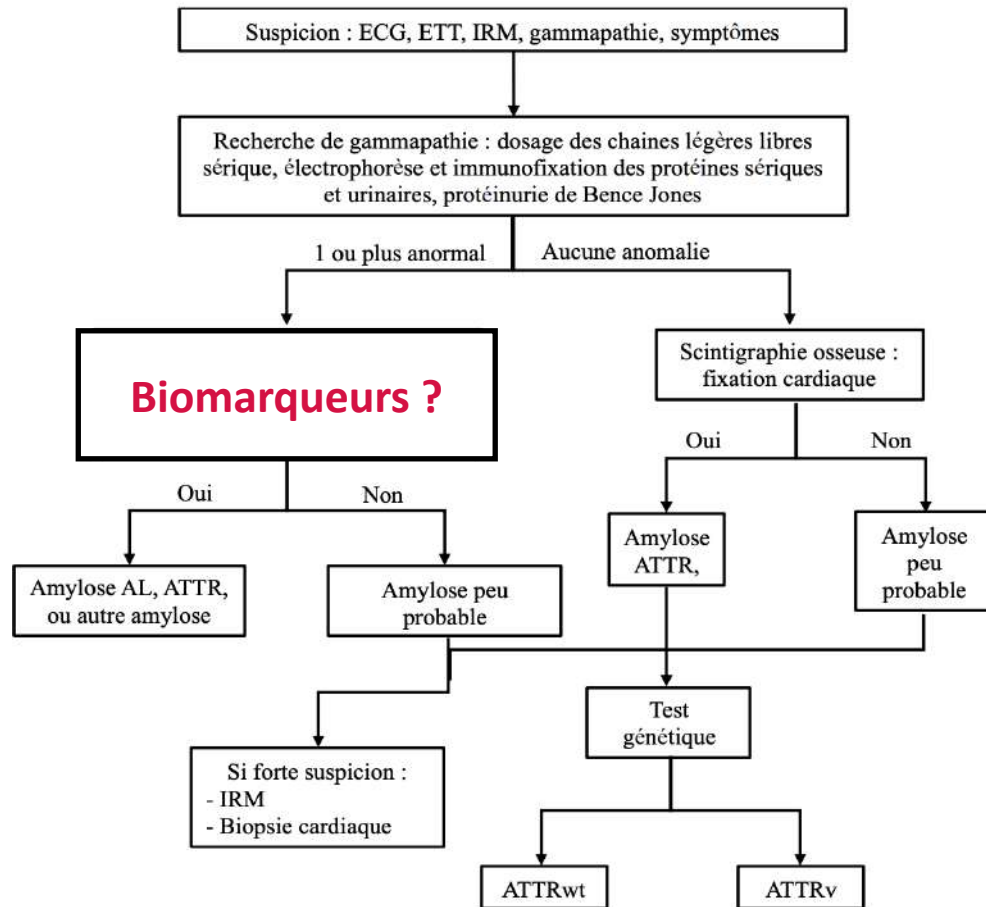
- ✓ Lié à **mutation SAA1**
- ✓ Sans syndrome inflammatoire
- ✓ Design d'un **Oligonucléotide antisens anti-SAA1** (IV 1/mois)

SAA plasmatique



Résultats (très) préliminaires de l'essai **NCT06397001**

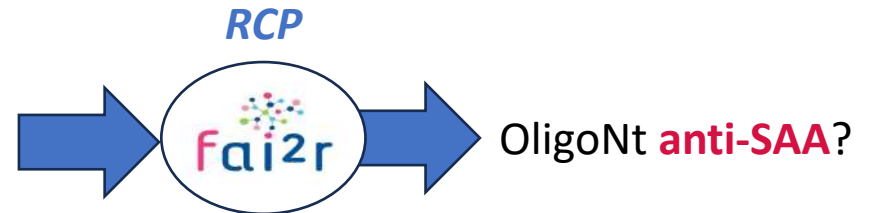
Diagnostic des ATTR et AL



Pour conclure

Traitement et suivi des AA

- ✓ Progression rénale
- ✓ SAA élevée





ISA INTERNATIONAL SOCIETY
OF AMYLOIDOSIS

MERCI POUR VOTRE ATTENTION !